



Volume: 3, Issue: 7, 1-4
July 2015
www.biosciencejournals.com
ISSN: 2321-9122
Impact Factor: 3.742

Oluwatosin K. Shittu
Tropical Disease Research
Unit, Department of
Biochemistry, Federal
University of Technology,
P.M.B.65, Minna, Nigeria

Bashir Lawal
Tropical Disease Research
Unit, Department of
Biochemistry, Federal
University of Technology,
P.M.B.65, Minna, Nigeria

Garba M. Haruna
Federal College of wild life
Management, New Bussa.
Niger State.

Eustace B. Berinyuy
Faculty of medicine and
Biomedical Science,
University of Yaounde 1,
Cameroon

Abubakar A. Yusuf
Department of Biochemistry,
IBB University Lapai, Niger
State, Nigeria

Aisha M. Ibrahim
Tropical Disease Research
Unit, Department of
Biochemistry, Federal
University of Technology,
P.M.B.65, Minna, Nigeria

Correspondence:

Bashir Lawal
Tropical Disease Research
Unit, Department of
Biochemistry, Federal
University of Technology,
P.M.B.65, Minna, Nigeria

Hepato-curative Effects of Methanol Extract from Nigerian Bee Propolis in Carbon Tetrachloride (CCl₄) Intoxicated Rats

Oluwatosin K. Shittu, Bashir Lawal, Garba M. Haruna, Eustace B. Berinyuy, Abubakar A. Yusuf, Aisha M. Ibrahim

Abstract

The hepatoprotective effects of methanol extracts from bee propolis against carbon tetrachloride (CCl₄) induced liver damage in albino rats were evaluated. Twenty rats of wister strains were group into 4 (A-D) of 5 rats each: Group A and B serves as normal control and CCl₄ control respectively while group C and D were treated with 600mg/kg methanol extracts of bee propolis and 100mg/kg Silymarin (Standard) respectively. The CCl₄ were administered in 72hrs interval intraperitoneally, while the extract was given daily for 10days through oral route. The ALT activities in serum and liver were significantly ($p < 0.05$) highest and Lowest respectively in negative control rats when compared with normal control and other experimental groups, however rat treated with propolis extract compared well ($p > 0.05$) with control value in their serum and liver ALT activities. The serum AST activities were significantly ($p < 0.05$) raised in negative control rats when compared with normal control and other experimental group. However, no significant ($p > 0.05$) difference were observed in Liver AST activities of all experimental groups when compared with the control values. The ALP activities in serum and liver were significantly ($p < 0.05$) lowest and highest respectively in negative control rats when compared with normal control and other experimental group. The liver ALP of rats treated with sylimarin and propolis compared well with the control value. The serum and Liver Total proteins were significantly ($p < 0.05$) highest in the control rats than all other experimental group. The serum and Liver Total proteins in propolis treated rats compared well ($P > 0.05$) with the negative control rats and were significantly higher than the sylimarin treated rats. In conclusion, bee propolis has ameliorated the adverse effects of CCl₄ induced Liver damage and could therefore, be recommended as an effective natural product for the management of liver disease

Keywords: bee propolis, hepatotoxic, biomarker enzymes, serum, liver

Introduction

Liver is the most important organs needed for survival, it plays a key role in the regulation of normal metabolic process in our system. Liver also play a significant roles in the elimination of toxic compounds/Xenobiotics and thus protect the body against adverse effect of drugs, chemicals toxin, bacteria, virus and parasite (Lawal *et al.*, 2015) ^[11]. Hence, in the process of these activities liver itself is subjected to variety of diseases and disorders. Any damage to liver can result in irregularities in the general metabolic process causing many disorders ranging from transient elevation in liver or serum enzymes to life threatening liver cirrhosis and hepatic failure (Bera *et al.*, 2012) ^[5], therefore the development of liver protective agents is of paramount importance in the protection from liver damage. Although notable development in modern medicine, hepatic disease remains a global health problem, thus the search for new drugs is still ongoing (Nithianantham *et al.*, 2011) ^[12]. So far no effective treatments in conventional or synthetic medicine that gives protection to the liver against damage or helps to regenerate hepatic cells (Bhandarkar *et al.*, 2004) ^[6]. Because of this fact efforts are being made to find suitable curative agents in natural products for the treatment of liver diseases.

Propolis is a gum-like product which is gathered by bees from various plants, and which varies in color from light yellow to dark brown. The composition of propolis varies with the source; generally, it is composed by 50% resin and vegetable balsam, 30% wax, 10% essential oils and aromatics, 5% pollen, and 5% other substances (Sforcin, 2007) ^[16]. It is known that the propolis has antibacterial, anticarcinogenic, and immunostimulating biological activities. Parts of these activities are probable due to the antioxidative effect of some compounds which occur

in relatively higher concentrations in propolis especially flavonoids (Guimarães *et al.*, 2012) [8]. In spite of the rich component and vast local use of *propolis* there is dearth of information on its' hepatoprotective activities. This study is therefore set out to evaluate the hepatoprotective potential of methanol extract from Nigerian bee propolis against CCL4 intoxicated rat, with a view of bridging the gap in knowledge and to scientifically validate the traditional uses of propolis in treating liver disease.

Materials and Methods

Collection of Bee propolis

Propolis material was collected from an apiary in Akure, Ondo State, Nigeria. The identity of the Propolis was authenticated by an Entomologist in the Department of Biological Sciences, Federal University of Technology, Minna, Nigeria, where a voucher specimen was deposited. The Propolis material was chopped in to small pieces and air dried in the Shade at room temperature for two weeks.

Experimental Animals

Healthy albino rats (1:1 male to female ratio) of average weight 120-150g were purchased from Animal House, University of Ibadan, Oyo State Nigeria. The rats were kept in clean plastic cages and maintained under standard laboratory conditions in the biochemistry laboratory, Federal University of Technology Minna till they reached the desired weight. They were allowed unrestricted access to rat pellets and water *ad-libitum*. The study was carried out according to the Guide for the Care and the Use of Laboratory Animals of the Institute of Laboratory Animal Resources, Commission of Life Sciences, National Research Council, USA (ILARCLA, 1997) [10].

Drugs and Chemicals

Sylimarin (silybin-140) was purchased from micro labs limited. All enzyme assay kits were products of Randox Laboratories Ltd, United Kingdom. All other reagents used were of analytical grade and were prepared in distilled water

Preparation of propolis extract

Preparation of the extract of Propolis material followed standard procedures (Shittu *et al.*, 2013) [17]. Two hundred grams of Propolis pellets were percolated in 1600 mL of absolute methanol and subsequently allowed to stand in the shade for 48 h before filtration, using Whatman No. 1 filter paper. The extract concentrate obtained was stored in airtight vials in the refrigerator at 4°C, until needed for bio-assay.

Experimental Design for Hepatoprotective Study

The animals were randomly assigned to five experimental groups of 5 animals each. The experimental groups are illustrated as follows:

Group1:- serve as Normal control and received no treatment

Group2:- serve as negative control and were administered 50 % carbon tetrachloride in liquid paraffin (2ml/kg body weight) for 9 days at 24hrs interval.

Group3:- serve as standard group received CCl₄ at 72hrs interval and Silymarin, a known anti-hepatotoxic drug at a dose of 100mg/kg daily for 9 days

Group 4:- received CCl₄ at 72hrs interval and 600mg/kg methanol extract from bee propolis daily for 9 days. All the animals were sacrificed on the 10th day. The blood and liver

was collected for estimation of biochemical parameters.

Collection of Blood and Liver

Collection of sample for biochemical analyses was as described previously (Shittu *et al.*, 2003). The animals were anesthetized with chloroform and blood was collected through cardiac puncture into a clean, dry centrifuge tubes. The blood sample was allowed to stand for 10minutes at room temperature and then centrifuged at 1000 rpm (503xg) for 15minutes to get the serum. The rat was dissected to reveal the internal organ and the liver was removed and placed in sample bottles containing 0.25 M sucrose solution to maintain a normal physiological environment. The liver was homogenized and the supernatant were stored in sample bottles for subsequent used.

Determination of Biochemical Parameters

The biochemical analyses were determined for Alkaline phosphatase (ALP) based on methods of Tietz, (1995) [18], Aspartate transaminase (AST) and alanine transaminase (ALT) as described by Reitman and Frankel, (1957) [15]. While the serum total protein concentration was estimated by biuret method as described by Gornall *et al.*, (1949) [7].

Statistical Analysis

Values were analyzed using statistical package for social science (SPSS) version 16 and presented as means \pm SE of the mean. Comparisons between different groups were carried out by one way analysis of variance (ANOVA) followed by Duncan's Multiple Range Test (DMRT). The level of significance was set at $P < 0.05$ (Adamu & Johnson, 1997) [1].

Results

Alanine transaminase Activities

Figure 1 shows the Liver and serum ALT activities in CCL₄ intoxicated rat treated with methanol extract of bee propolis. The ALT activities in serum and liver were significantly ($p < 0.05$) higher and Lower respectively in CCL₄-hepatotoxic rats when compared with normal control and other experimental group. Group treated with sylimarin also show the same pattern with CCl₄ group when compared with the control value. However, CCL₄ intoxicated rats treated with bee propolis (600mg/kg) compared well ($P > 0.05$) with the control value.

Aspartate transaminase activities

Figure 2 shows the Liver and serum AST activities in CCL₄ intoxicated rats treated with methanol extract of bee propolis. The serum AST activities were significantly ($p < 0.05$) raised in CCL₄-hepatotoxic rats when compared with normal control and other experimental group. The serum AST activities in rats treated with sylimarin (100mg/kg) compared well ($P > 0.05$) with the control value, but lower than those treated with bee propolis (600mg/kg). However, no significant ($p > 0.05$) difference were observed in Liver AST activities of all the experimental group when compared with the control values

Alkaline phosphatase

Figure 3 shows the Liver and serum ALP activities in CCL₄ intoxicated rat treated with methanol extract of bee propolis. The ALT activities in serum and liver were significantly ($p < 0.05$) lowest and highest respectively in CCL₄-hepatotoxic

rats when compared with normal control and other experimental group. The liver ALP of rats treated with sylimarin (100mg/kg) and propolis (600mg/kg) compared well with the control value, but were significantly raised in serum ALP activities than the control rats.

Total proteins

The serum and Liver Total proteins were significantly ($p < 0.05$) highest in the control rats than all other experimental group. The serum and Liver Total proteins in propolis treated rats compared well ($P > 0.05$) with the CCL4 intoxicated rats and were significantly higher than the sylimarin (100mg/kg) treated rats (Figure 4)

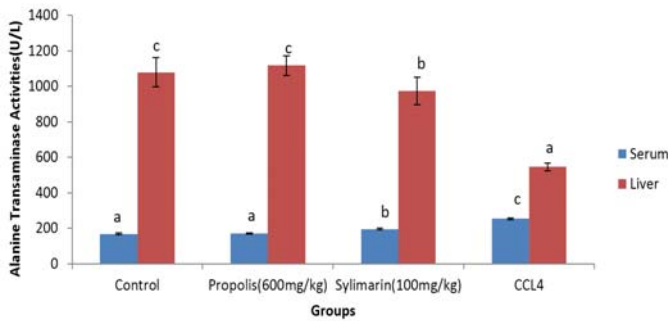


Fig 1: Serum and Liver ALT activities in CCL4 intoxicated rats

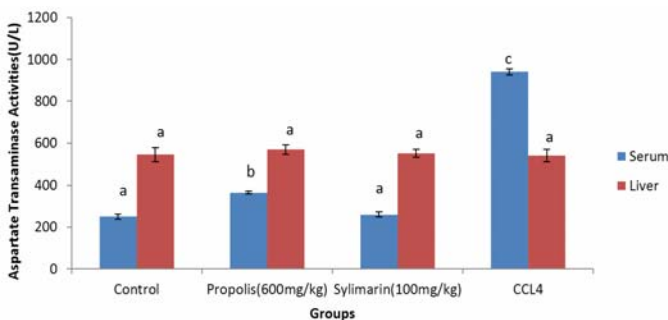


Fig 2: Serum and Liver AST activities in CCL4 intoxicated rats

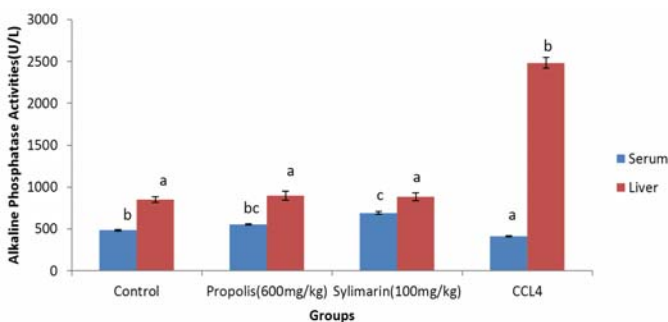


Fig 3: Serum and Liver ALP activities in CCL4 intoxicated rats

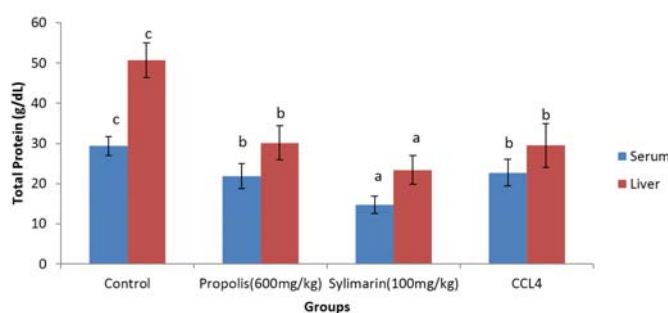


Fig 4: Serum and Liver Total protein in CCL4 intoxicated rats

Discussion

Treatment of diseases associated with the liver is very vital, and must be done with importance and extensive care. Many herbal remedies for liver diseases are known but only a few of them have been pharmacologically assessed for their efficacy. It is very important to assess natural products for their efficacy in the treatments they are used for. It is especially very important to assess remedies for liver diseases due to the liver's fragility and relation to other vital organs, and yet its numerous vital roles detrimental to the survival of a person (Nusrat, 2010) [13].

Estimation of biochemical indices has been widely accepted as a bio-indicator of liver damage. A number of studies have reported that CCl4 damages the hepatocyte with the consequent release of enzymes into the serum (Ashok *et al.*, 2002) [4]. The significant decrease in liver ALT activities with a consequent increase in serum activities of CCl4-hepatotoxic rats is obviously as results of the leakages of this enzyme from the liver. However, the fact that ALT activities (which is the most precise determinant for assessing hepatoprotectivity in biochemical analysis) in serum and liver of CCL4 intoxicated rats treated with bee propolis at 600mg/kg compared well ($P > 0.05$) with the control value suggests that the extract was able to reverse the injurious effects of CCl4, or did not enable CCl4 to cause pronounced injury in the cells.

The increase in serum AST activities without consequent increase in the liver AST activities CCl4-hepatotoxic rats suggest the leakage of this enzyme from tissue other than liver. However the serum AST activities in rats treated with sylimarin (100mg/kg) compared well ($P > 0.05$) with the control value. This effect suggests that the liver's integrity has been preserved by the propolis despite the CCL4 intoxication.

The activities of ALP in organs and body fluid are widely accepted as a biomarker of plasma membrane and endoplasmic reticulum and are often used to assess the integrity of the plasma membrane and endoplasmic reticulum (Akanji *et al.*, 1993) [3]. CCL4 administration induced liver damage as evident by alteration in serum and liver ALP activities in intoxicated rats. The reduction in ALP activities in serum may be attributed to either or inhibition of the enzyme molecules by the propolis extract or inactivation of the enzyme molecules in situ (Hassan *et al.*, 2010) [9]. Similarly, the elevated levels of ALP in liver of intoxicated rats may be attributed to activation of the enzyme molecule in situ. Such increase in ALP activities could constitute threat to the life of cells that are dependent on a variety of phosphate esters for their vital process since the cells might be deprived of the much needed energy as a result of indiscriminate hydrolysis of the phosphate ester (Oyewo *et al.*, 2012) [14]. These alterations will have their consequential effects on the normal functioning of the enzymes in the animals. However, the fact the liver ALP of rats treated with sylimarin (100mg/kg) and propolis (600mg/kg) compared well with the control value, suggest that the propolis have some functions in preserving structural integrity of hepatocellular membrane.

The concentrations of total proteins, is also an important indicator of normal or impaired functions of liver. The observed decrease in the total proteins in Liver and serum of all the experimental rats when compared with the control rats suggests a compromise of the synthetic ability of the liver arising from the CCL4 administration. Such decrease in total

protein could, however, lead to hydration which is detrimental to cellular homeostasis. This will negatively affect the metabolic activities of the liver and consequently the health of the animals (Adeyemi *et al.*, 2012) [2]. However the propolis exert no significant protective effect on liver as far as this metabolites is concern. In conclusion, bee propolis has ameliorated the adverse effects of CCL₄ induced Liver damage and could therefore, be recommended as an effective natural product for the management of liver disease

References

1. Adamu SO, Johnson TL. Statistics for Beginners, Book 1. SAAL. Publications, Ibadan, Nigeria. 1997; 184-199.
2. Adeyemi OS, Fambegebe M, Daniyan OR and Nwajei I. Yoyo Bitters, a polyherbal formulation influenced some biochemical parameters in Wistar rats. *J Basic Clin Physiol Pharmacol* 2012; 12; 0 (0):1-4.
3. Akanji MA, Olagoke OA, Oloyede O B. Effect of chronic consumption of metabisulphite on the integrity of the rat kidney cellular system. *Toxicology*, 1993; 81: 173-179
4. Ashok K, Somayayi S, Bairy S, Hepatoprotective effect of *Ginkgo biloba*, *Indian J. Pharmacol.* 2002; 33:260-266
5. Bera TK, Chatterjee K, Jana K, Ali KM, De D, Maiti S, *et al.* Antihepatotoxic effect of “Livshis,” a polyherbal formulation against carbon tetrachloride-induced hepatotoxicity in male albino rat. *J Nat Pharm* 2012; 3: 17-24.
6. Bhandarkar M, Khan A. Anti-hepatotoxic effect of *Numphae stellata* wild against carbon tetrachloride hepatic damage in albino rats. *J. Ethnopharmacol.* 2004; 91: 61-64.
7. Gornall AC, Bardawill CJ, David MM. Determination of serum protein by means of biuret reaction. *Journal of Biol Chem.* 1949; 177:751-756
8. Guimarães NS, Mello JC, Paiva JS, Bueno PC, Berretta AA, Torquato RJ, Nantes IL, Rodrigues T. *Baccharis dracunculifolia*, the main source of green propolis, exhibits potent antioxidant activity and prevents oxidative mitochondrial damage. *Food Chemistry Toxicology* 2012; 50 (3-4) 1091-1097
9. Hassan SW, Salawu K, Ladan MJ, Hassan LG, Umar RA, Faihu MY. Hepatoprotective, Antioxidant and Phytochemical Properties of Leaf Extracts of *NewbouldiaLaevies*. *International Journal of Pharm Tech Research.*, 2010; 2(1): 573-584,
10. Institute of laboratory animal resources, commission on life sciences, National Research Council. *Occupational Health and Safety in the Care and Use of Research Animals*, Washington, DC: National Academy Press; 1997
11. Lawal B, Shittu OK, Ossai PC, Abubakar, AN, Ibrahim AM. Antioxidant Activities of Giant African Snail (*Achachatina maginata*) Haemolymph against CCL₄-Induced Hepatotoxicity in Albino Rats. *British journal of pharmaceutical research.* 2015;6(3): 141-154
12. Nithianantham, K, Shyamala M, Chen Y, Latha LY, Jothy SL. Sasidharan S. “Hepatoprotective Potential of *Clitoria ternatea* Leaf Extract Against Paracetamol Induced Damage in Mice,” *Molecules*, vol. 16, pp. 10134-10145, 2011.
13. Nusrat, A.H. (2010) Hepatoprotective And Toxicological Assessment Of *Spondias Mombin* L. (Anacardiaceae) In Rodents A Thesis Kwame Nkrumah University Of Science and Technology, Kumasi
14. Oyewo EB, Akanji MA, Iniaghe MO and Fakunle PB. Toxicological Implications of Aqueous Leaf Extract of *Andrographis paniculata* in Wistar Rat. *Nature and Science* 2012; 10(2):91-108.
15. Reitman S, Frankel SA. Colorimetric method for the determination of serum glutamic oxalacetic and glutamic pyruvic transaminases. *American Journal of Clinical Pathology.* 1957; 28:56-63.
16. Sforzin J.M., Propolis and the Immune System: a review, *Journal of Ethnopharmacology* Vol. 113, 2007, pp. 1-14
17. Shittu OK, Olayemi IK, Omalu ICJ, Adeniyi AK. Antiplasmdial properties of methanolic extract of *Muscadomestica maggot* on *P. berghei* infected mice. *International journal of biology pharmacy and allied science.* 2013; 2(5): 1064-1070
18. Tietz NW. *Clinical Guide to Laboratory Tests.* 3rd edn. Philadelphia: W.B. Saunders. 1995; 286-288.
19. Yakubu MT, Bilbis LS, Lawal M, Akanji MA. Effect of repeated administration of sildenafil citrate on selected enzyme activities of liver and kidney of male albino rats. *Nigerian Journal of Pure and Applied Sciences.* 2003; 18:1395-1400.